

Brain-Tumor-Detection-Using-Digital-Image-Processing

PRAVEEN KUMAR

Prof. Shubham, Dept. of Electronics & Communication Engineering, Kalinga University Raipur, Chhattisgarh, India

Abstract – Computer Tomography(CT) is one of the best technologies currently being used for diagnosing brain tumor. A brain tumor, defined as an abnormal growth of cells within the brain or the central spinal canal. Brain tumors include all tumors inside the central spinal canal. They are created by an abnormal and uncontrolled cell division, usually in the brain itself, but also in lymphatic tissue, in blood vessels, in the cranial nerves. This damage can cause change in alertness including Dysfunction, Consequences of intracranial hypertension and Irritation. Thus tumor detection needs to be fast enough as the patient cannot recover if the damage is more than 50%. For detecting this tumor CT scan is done. This CT scan images are taken for this project to process it. The CT-scan images are used for the operation purpose to detect the correct area of the brain that is infected. as there occurs the false detection also, the detection is done in the radiology lab by an expert doctor seeing the tumor directly based on his experience thus it can have chances to get the false detection, for this there is no other technique to detect the tumor instead by detecting it manually seeing the CT scan. Using digital image processing this tumor can be find more precisely and fast detection can be done.

Key Words: - Computed tomography (CT), Gray-Scale Image, MATLAB digital image processing etc.

1.INTRODUCTION

Tumor is the most common and most aggressive malignant primary brain tumor in human, involving glial cells and accounting for 52% all functional tissue brain tumor cases and 20% of all intracranial tumors. The term “glioblastoma”, also known as Grade IV Astrocytoma GBM is rare disease which presents two variants: Giant cell glioblastoma and gliosarcoma. Most glioblastoma tumors appear to be Sporadic, without any genetic predisposition. Tumor are intracranial neoplasm occurs when abnormal cells form within the brain. There are two types of Brain-

- Malignant or cancerous tumor
- Benign Tumor

Risk factor that may occasionally be involved include a number of genetic syndrome such as neurofibromatosis as well as exposure to the chemical vinyl chloride, Epstein-barr virus and ionizing radiation.

Tumors can be benign or malignant, can occur in different parts of the brain, and may or may not be primary tumors. A primary tumor is one that has started in the brain, as opposed to a metastatic tumor, which is something that has spread to the brain from another part of the body. Tumors may or may not be symptomatic some tumors are discovered because the patient has symptoms, others show up incidentally on an imaging scan, or at an autopsy. The most common primary brain tumors are

- Gliomas
- Meningiomas
- Pituitary adenomas
- Nerve sheath tumors

The detection of tumor is performed in two phases: Preprocessing and Enhancement in the first phase and segmentation and classification in the second phase.

1. Proposed Methodology

1.1 Anaplasia- or dedifferentiation; loss of differentiation of cells and of their orientation to one another and blood vessels, a characteristic of anaplastic tumor tissue. Anaplastic cells have lost total control of their normal functions and many have deteriorated cell structures. Anaplastic cells often have abnormally high nuclear-to-cytoplasmic ratios, and many are multinucleated. Additionally, the nuclei of anaplastic cells are usually unnaturally shaped or oversized nuclei. Cells can become anaplastic in two ways: neoplastic tumor cells can dedifferentiate to become anaplasias (the dedifferentiation causes the cells to lose all of their normal structure/ function), or cancer stem cells can increase in their capacity to multiply (i.e., uncontrollable growth due to failure of differentiation).

1.2 Atypia- is an indication of abnormality of a cell (which may be indicative for malignancy). Significance of the abnormality is highly dependent on context.

1.3 Neoplasia- is the (uncontrolled) division of cells; as such neoplasia is not problematic but its

consequences are: the uncontrolled division of cells means that the mass of a neoplasm increases in size, and in a confined space such as the intracranial cavity this quickly becomes problematic because the mass invades the space of the brain pushing it aside, leading to compression of the brain tissue and increased intracranial pressure and destruction of brain parenchyma. Increased Intracranial pressure (ICP) may be attributable to the direct mass effect of the tumor, increased blood volume, or increased cerebrospinal fluid (CSF) volume may in turn have secondary symptoms.

1.4 Necrosis- is the (premature) death of cells, caused by external factors such as infection, toxin or trauma. Necrotic cells send the wrong chemical signals which prevents phagocytes from disposing of the dead cells, leading to a build up of dead tissue, cell debris and toxins at or near the site of the necrotic cells. Arterial and venous hypoxia, or the deprivation of adequate oxygen supply to certain areas of the brain, occurs when a tumor makes use of nearby blood vessels for its supply of blood and the neoplasm enters into competition for nutrients with the surrounding brain tissue. The skull bone structure can also be subject to a neoplasm that by its very nature reduces the volume of the intracranial cavity, and can damage the brain.

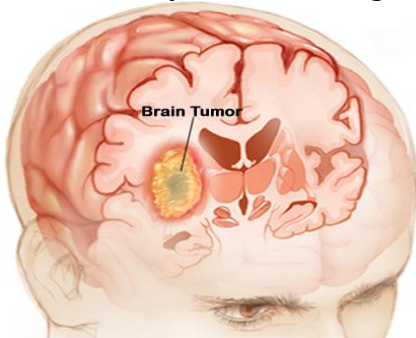


Fig. 1.1- Brain Tumor

2.1 Project details

The CT Scan technique is used for the monitoring the images of brain part which is damaged. In this CT Scans the images are shown in the form of gray scale images and the above image shows the RGB component, this RGB component is not visible in the CT Scans. The images shows the parietal section of the head in this the Cerebrum is shown in the form of the gray color while the veins and the artery in the form of creamish white color. And any clotting the brain that causes some sort of damage can be detected as dark gray in color. thus there is need to convert this images in the gray scale images and then extract the parameters

from it. The parameters extraction are like taking out the per pixel information and then plotting it , in CT-Scan the images are shown in this manner tumor appears white in color and brain damaged cells in totally black color , thus the values of the pixel showing the brain damaged cells are 0 and that of the tumor is 1, thus extracting this we can check and plot the tumor in MATLAB. This damaged patient image can be differentiated with the normal patient image and we can get the tumor.

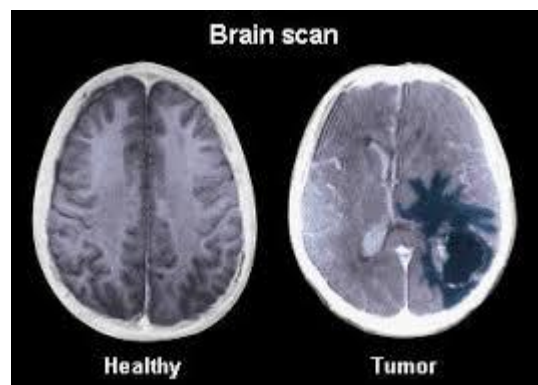


Fig. 2.1- CT Scan of Brain Tumor

2.2 Flow chart of the project Image Acquisition CT Scan

Computed Tomography (CT) is a scanning technique allowing the generation of tomographic images of every part of the human body without superimposition of adjacent structures it is a procedure that uses special X-ray equipment to create cross-sectional pictures the body. CT images are produced using X-ray technology and powerful computers. The images are obtained from the CT -Scans centers which are in the form of gray images, these images are then taken for the image processing. Though these images which looks like gray images they are having the RGB components and the image properties as 512 x 512 x 3. The uses of CT include looking for

- Broken bones
- Cancers
- Blood clots
- Signs of heart disease
- Internal bleeding

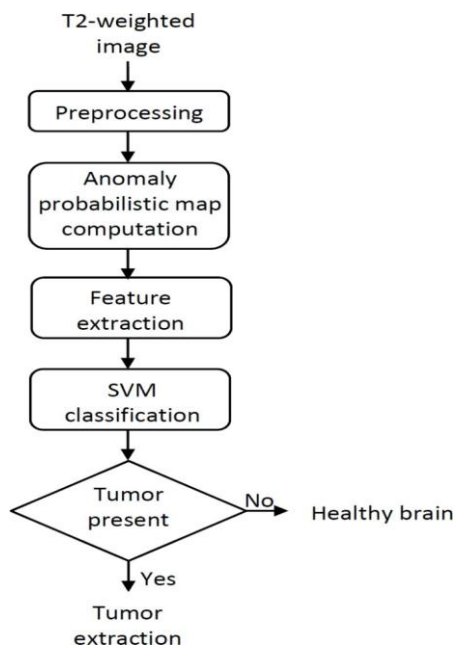
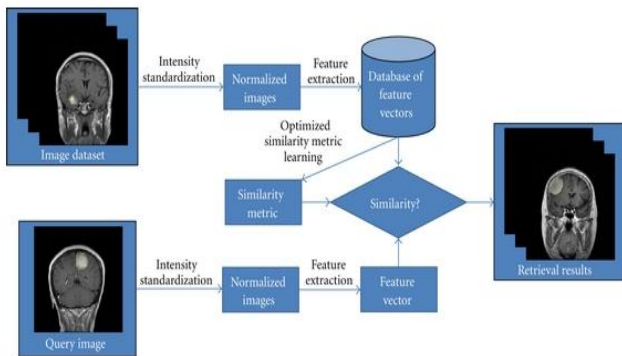


Fig2.2-Flow chart of the Brain Tumor

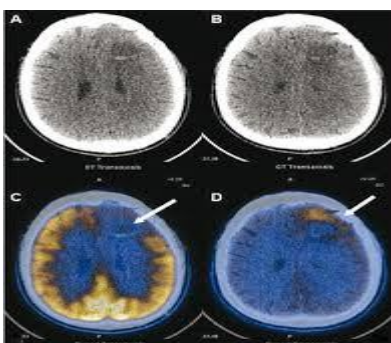


Fig2.3- Brain Tumor

2.3 Brain Images

The C.T Scans images shown in the Fig 2.1(a) is taken from the frontal and the centripetal side of the head .This image is of the normal person who is not having

any type of tumour or any type of injury to the brain, in this image there is white boundary which resembles the bone structure of the head where as the gray color resembles the brain (gray matter). This image is having the property of 512 x 512 x 3 for further analysis of the image this image must be converted to the gray scale image.

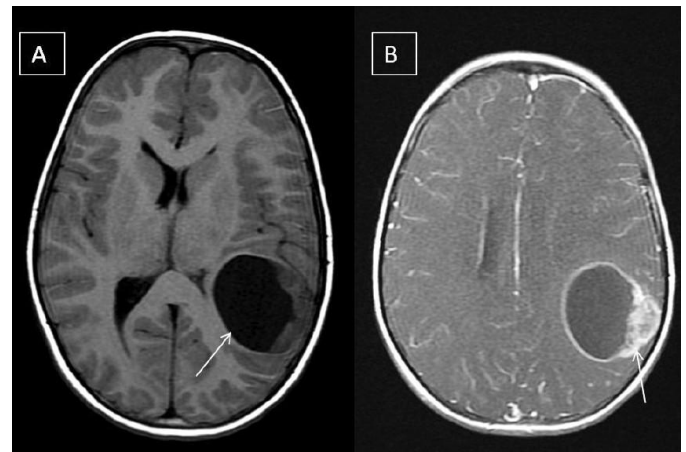


Fig-Gray-Scale Image

2.4 Gray-Scale Image

The images received from the CT Scans must be converted to the Gray scale image because though the images are in gray matter the Red Green Blue components are not visible in the image. Thus removing of this RGB component will help to perform the operations easily. This RGB images are converted to grayscale images by eliminating the hue and saturation information while retaining the luminance. Thus making the property of the image 512 x 512 x 3 to 512 x 512.

3.Parameter Extractions

| | | | | | | | |
|-----|-----|-----|-----|-----|-----|-----|-----|
| 0 | 3 | 3 | 0 | 130 | 131 | 131 | 165 |
| 215 | 215 | 115 | 220 | 115 | 115 | 215 | 215 |
| 215 | 131 | 133 | 255 | 255 | 255 | 215 | 215 |
| 215 | 118 | 135 | 255 | 255 | 255 | 215 | 111 |
| 215 | 168 | 144 | 255 | 255 | 255 | 138 | 115 |
| 215 | 137 | 164 | 187 | 171 | 171 | 137 | 114 |
| 0 | 138 | 154 | 165 | 236 | 171 | 171 | 215 |
| 215 | 215 | 215 | 215 | 0 | 215 | 115 | 215 |

Fig-Matrix form Of Brain Tumor

Fig 3.4 (a) In this phase of project the data from the C.T scans are acquired and converted to the gray scales images now the parameters extracted are as follows

- 1) The image is converted in the matrix form.
- 2) The matrix form are then scanned on the X-Axis as well as Y -Axis
- 3) In the scanning if the pixel value is found out to be 0 or 255 then it is displayed and noted.
- 4) After scanning the pixel having the value 255 or 0 are then searched for there location that if they are having the surrounding values to be 0 or 255 if it forms a 3 x 3 matrix or greater.

Conclusion

The tumors can be found precisely according to the length, breadth and the exact position of the infected area, these project can help the doctors for the analysis of the tumor and also the damage to the brain in stages i.e in which stage the patient is.

References

[1] "General Information About Adult Brain Tumor". NCI. 2014-04-14. Retrieved 8 June 2014.

[2] "Adult Brain Tumors Treatment". NCI. 2014-02-28. Retrieved 8 June 2014.

[3] Longo, Dan L (2012). "369 Seizures and Epilepsy". *Harrison's principles of internal medicine (18th ed.)*. McGraw-Hill. p. 3258. ISBN 978-0-07-174887-2.

[5] *World Cancer Report 2014*. World Health Organization. 2014. pp. Chapter 5.16. ISBN 9283204298.

[6] "SEER Stat Fact Sheets: Brain and Other Nervous System Cancer". NCI. Retrieved 18 June 2014.

[8] *World Cancer Report 2014*. World Health Organization. 2014. pp. Chapter 1.3. ISBN 9283204298.

[9] "Brain Tumor Facts 2011". Brain Tumor Alliance Australia. Archived from the original (PDF) on 20 Nov 2014. Retrieved 9 June 2014.


[10] Kristian Sandberg, Introduction to image processing in Matlab.

[11] Kim J.K., Park H.W. (1999) IEEE trans. Med. Image., 18(3), 231-238.

[12] Bird R.E., Wallace T.W. and Yankaskas B.C. (1992) Analysis of Cancers missed at screening mammography Radiology, 184(3), 613-617.

[13] Livier C., Maxime S., Pierre-y, Indiau H., Delingette S., Warfield K., Gregoire M. and Nicholas A. (2005) IEEE on Medical Imaging, 24.

BIOGRAPHIES

| | |
|---|--|
|  | <p><i>Praveen Kumar, M. Tech Scholar, Department of Of Electronics & Communication Engineering, Kalinga University Raipur, Chhattisgarh, India. I completed my B.E (Electronics & Telecommunication Engineering) in 2014 from RCET Bhilai. I am having good interest in digital image processing and analysis.</i></p> |
|---|--|