

Survey Based on Detection of Optic Disc in Retinal Images Using Segmentation Based Techniques

D Binny Jeba Durai¹, Dr. T. jaya²

¹Udhya Polytechnic College, Vellamadam.

²CSI Institute of Technology, Thovali.

Abstract— Automated localization and detection of the optic disc (OD) is an essential step in the analysis of digital diabetic retinopathy systems. Accurate localization and detection of optic disc boundary is very useful in proliferative diabetic retinopathy where fragile vessels develop in the retina. Detection of optic disc area is complex because it is located in an area that is considered as pathological blood vessels. The optic disc appears as a round region usually brighter than the surrounding. The results achieved by different algorithms can be compared when algorithms are applied on the same standard databases. In this paper we compare the eccentricity, accuracy and brightness using different segmentation techniques.

Keywords — optic disc, segmentation, fundus image, detection

I. INTRODUCTION

Diabetic Retinopathy (DR) is a result of long term diabetes mellitus and is a significant growing public health problem. It is one of the predominant causes of blindness. It causes pathological changes of the retina such as microaneurysms, intraretinal microvascular abnormalities, venous bleeding and neovascularities as well as haemorrhages, exudates and retinal oedema. Regular screening of Diabetic Retinopathy is indispensable so that appropriate and timely treatment can be given which thereby reduces the incidence of impaired vision and blindness from this condition. Current methods of detection and assessment of diabetic retinopathy are manual, expensive and require highly trained personnel to read large number of fundus images. The efficiency can be improved by automating the initial task of analyzing the huge amount of retinal fundus images.

The optic disc is the brightest part in fundus images that can be seen as a pale, round or slightly oval disk. It is the entrance region of blood vessels and also acts as a landmark and reference for the other features in the fundus image. There are several methods for optic disc detection.

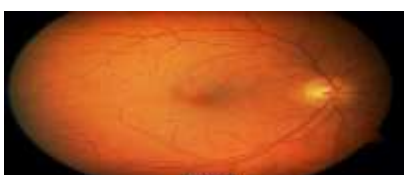

Fig 1. Original Retinal Fundus Image

II. LITERATURE REVIEW

Frank ter Haar [6] applied illumination equalization to the green-band of the image, and then a resolution pyramid using a simple Haar-based discrete wavelet transform was created. Finally, the brightest pixel at the fifth level of the resolution pyramid was chosen to correspond to the OD area. They also proposed an alternative to the later method based on the pyramidal decomposition of both the vasculature and the green-band, where the fifth level of the resolution pyramid for both the illumination equalized green-band and the binary vessel segmentation are summed, and the highest value corresponds to the OD center.

Hough transform [4] is a technique capable of finding geometric shapes within an image and was employed to detect the OD. The Hough transform uses a couple of methods. In the first one, Hough transform was applied only to pixels on or close to the retinal vasculature in a binary image of the vasculature. The binary vasculature was dilated in order to increase the possible OD candidates. Alternatively, in the second method Hough transform was applied once again but only to the brightest 0.35% of the fuzzy convergence image obtained. Once more, dilation was applied to the convergence image to overcome the gaps created by small vessels. The center and boundary of the optic disc are found by applying the Hough transform to the gradient image. The Hough transform is a method for finding shapes in an image. The basic idea behind the Hough transform is to transform the image into a parameter space that is constructed specifically to describe the desired shape analytically. Maxima in this parameter space then correspond to the presence of the desired shape in image space.

The circular hough transform (CHT) is used to detect the OD which has a roughly circular shape. The retinal vasculature in the green-band image was suppressed using the closing morphological operator. The Sobel operator and a simple threshold were then used to extract the edges in the image. CHT [8] was finally applied to the edge points, and the largest circle was found consistently to correspond to the OD. This is suitable for normal healthy fundus images where in optic disc is alone the brightest region of the image. But our

images contain exudates and lesions. The exudates' intensity value is similar to that of optic disc. If it is small in size then it can be characterized by the intense pixels density. But in some images the exudates are as large and dense as exudates. In such cases it is difficult to find which of the candidate contains the optic disc.

Fuzzy convergence [2] is a novel voting type algorithm developed by Hoover and Goldbaum in order to determine the origination of the retinal vasculature (convergence point), and thus, localize the OD which is considered the only consistently visible property of the OD. The inputs to the fuzzy convergence algorithm were six binary vessel segmentations (each at a different scale) obtained from the green-band image. Each vessel was modeled by a fuzzy segment, which contributes to a cumulative voting image (a convergence image) where each pixel equals the amount of fuzzy segments on which the pixel lied. Finally, the convergence image was smoothed and thresholded to determine the strongest point of convergence. If the

final result was inconclusive, the green-image was illumination equalized, and Fisher's linear discriminant was applied to regions containing the brightest pixels to detect the OD.

K-means clustering [9] is a vector quantization method, which is initially from signal processing, that is common for cluster analysis in data mining. The main aim of K-means clustering is to divide n observations into k clusters in which each observation fits to the cluster with the nearest mean. Once the image is resized and adaptive histogram is applied, clustering algorithm is applied on image. Cluster analysis is a key technique for reducing a mountain of rare data to a pile of meaningful information. It shrinks data which creates subgroups that are more manageable than individual datum. Once K-mean clustering algorithm is applied on the histogram image optic disc is detected in segmented image. After detecting optic disc in segmented we apply Mathematical Morphology (MM) on the segmented image by using disc shape structuring element.

III. METHODOLOGY

The various methods adopted in optic disc detection is discussed below.

A. Pre-processing

The original (RGB) image is transformed into appropriate colour space for further processes. And then, filtering technique is used to reduce the effect of noise. After using the filtering technique, the noise such as salt and pepper noise are removed from the image. Then contrast-limited adaptive histogram equalization (CLAHE) is used for image enhancement. Unlike histogram, it operates on small data regions rather than the entire image. This function uses a contrast-

enhancement method that work significantly better than regular histogram equalization for most images.

B. Converting Colors from RGB to HSI

In digital image, the input image can be the RGB (Red, Green, and Blue) images or other. The RGB image can be described as $M \times N \times 3$ array of colour pixels. In this paper, the RGB input image is transformed into HSI colour space for further processes.

C. Optic Disc Segmentation

We perform the segmentation using the grey level image F_{odcr} , which contains all the information necessary. However, the high contrast of the blood vessel inside the optic disc misguides the segmentation energy functional and breaks the continuity of the optic disc boundary.

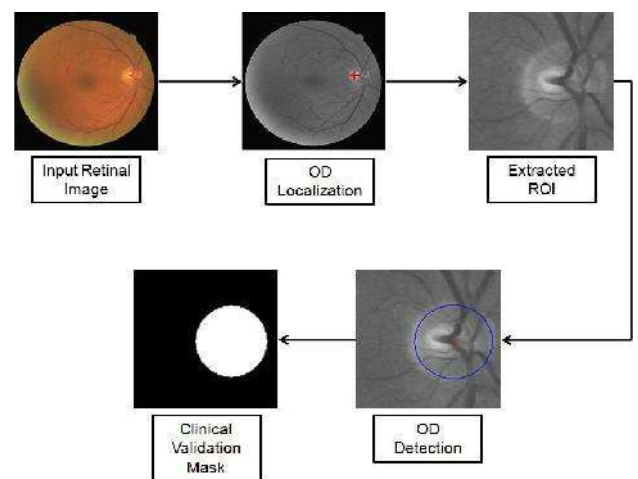


Fig. 2. Retinal images with lesions and distorted shape of optic disc

Therefore, we apply the morphological closing operation to remove the blood vessels, and the vessel removed image (F_{vr}) is obtained.

D. Threshold estimation

In normal, healthy retinal images, OD is mostly the brightest region. However, in retinal images affected due to diseases such as diabetic retinopathy, there may exist other bright regions in addition to OD. So first we detected all bright regions within retinal images. In paper by Li and Chutatape [22], they used the highest 1% gray levels in intensity image to obtain threshold value to detect candidate bright regions. However, there is possibility of not detecting OD as candidate region if highest 1% gray levels are occupied by other bright regions within image.

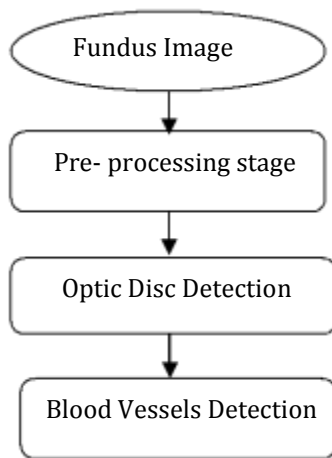


Fig 3. Flow Chart for Optic Detection

E. Image Enhancement

The result image of the median filter is enhanced by using the histogram equalization technique. The histogram equalization technique is used to overcome the uneven-illumination case. There are two methods to enhance the image: Histogram equalisation and Adaptive histogram equalisation.

IV. BASIC ALGORITHM FOR DETECTION OF CANDIDATE REGION FOR OD

- Step 1: Estimate Threshold.
- Step 2: Apply Threshold and identify bright regions.
- Step 3: Select candidate regions which satisfy area criterion.
- Step 4: Select candidate region which satisfies density criterion.
- Step 5: If no candidate region is selected, reduce threshold
- Step 6: If threshold is greater than zero, apply steps 2 through 5.
- Step 7: Stop.

However, it is probably for binary segmentation that these operations are most useful. Therefore, in the second stage, a global image threshold is used to convert an intensity image to a binary image, separating brighter regions from dark background. A global threshold (level=graythresh (image_close)) that can be used to convert an intensity image to a binary image with im2bw(image_close, level) is a normalized intensity value that lies in the range [0, 1]. The graythresh function chooses the threshold to minimize the intraclass variance of the black and white pixels.

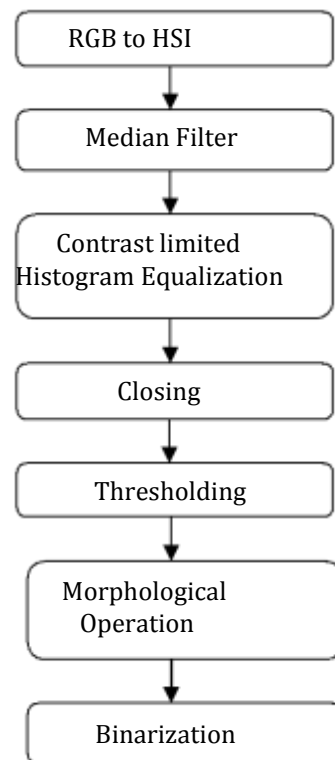


Fig 4. Flow Chart for Detection of Candidate Region

V. RESULTS AND DISCUSSION

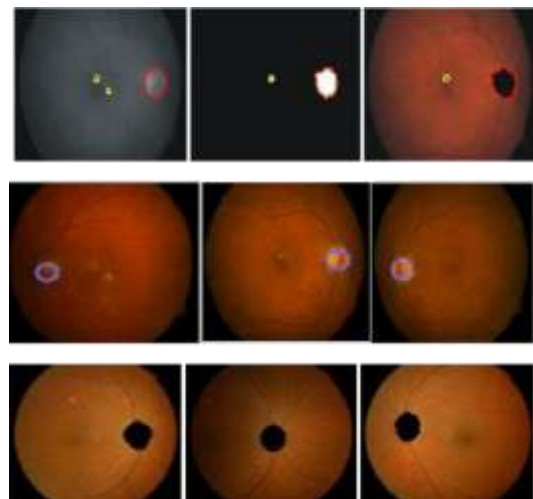


Fig 5. Detection Of Optic Disc Using K-Means Clustering, Hough Transform And Fuzzy Convergence

We recorded the optic disc region in each of the retinal images in this system by determining it manually in order to evaluate the performance of our study. We measured the accuracy of different segmentation techniques with the information of measured algorithms.

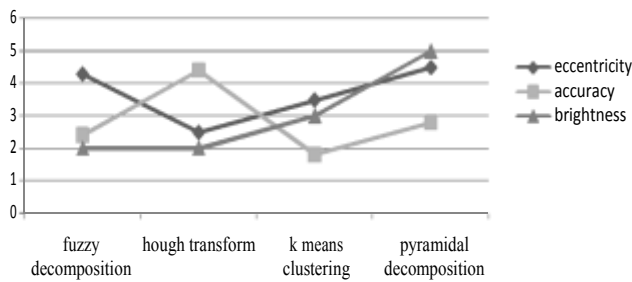


Fig 6: Comparison of Different Segmentation Techniques

Table 1: Comparison for Accuracy

Method Used	OD Detected	% Accuracy
K-means clustering	126	96.92
Hough transform	86	93.2
Fuzzy convergence	40	95.2

VI. CONCLUSION

. During the research and the development of this work, it was possible to better understand that the input image is in RGB color space and for the further processes the image is converted into appropriate color space. The median filter is used for the noise reduction without blurring the edge. And then various other transform method were used. The results of our work can play a major role in the screening of eye diseases.

ACKNOWLEDGMENT

We are thankful to God almighty and the supporting contributors for the well being of our work.

REFERENCES

[1] Siddalingaswamy C , Gopalakrishna rabhu K ,“Automatic localization and boundary detection of optic disc using implicit active contours”, Internation Journal of Computer Applications, vol. 1, no. 7, pp. 1-5, 2010.

[2] Michael D. Abramoff, Meindert Niemeijer, “The automatic detection of the optic disc location in retinal images using optic disc location regression”, Conf roc IEEE Eng Med Biol Soc , 1: pp 44 2- 4435, 2006.

[3] Jaspreet Kaur, Dr. Sinha, “Automated localization of optic disc and macula from fundus images”, International Journal of Advanced Research in Computer Science and Software Engineering, vol. 2, Issue 4, pp. 242-249, April 2012.

[4] Healey PR, Mitchell P, Smith W, Wang JJ, “Relationship between cup- disc ratio and optic disc diameter”, the Blue Mountains Eye Study, Aust N Z J Ophthalmol.; 25 Suppl 1:S99-101, May 1997.

[5] Rafael C. Gonzalez, Richard E. Woods, Steven L.Eddins, Digital Image Processing Using MATLAB, 2nd Edition, Prentice-Hall, 2002 (Size 8) S. M. Metev and V. P. Veiko, Laser Assisted Microtechnology, 2nd ed., R. M. Osgood, Jr., Ed. Berlin, Germany: Springer-Verlag, 1998.

[6] A. Dehghani, H. Moghaddam, and S. Moin, “Optic disc localization in retinal images using histogram matching,”EURASIP Journal on Image and Video Processing, vol. 2, no.19, pp. 1687--5281, 2012.

[7] S. Sekhar, W. Nuaimy, and A. Nandi, “Automated localization of retinal optic disc using Hough transform,” IEEE International Symposium on Biomedical Imaging: From Nano to Macro,2008.

[8] D. Godse and D. Bormane, “Automated localization of optic disc in retinal images,” International Journal of Advanced Computer Science and Applications, vol. 4, no. 2, 2013.

[9] P. Healey, P. Mitchell, W. Smith, and J. Wang, “Relationship between cup-disc ratio and optic disc diameter,” Australian and New Zeland Journal of Ophthalmology, 1997.

[10] G. Joshi, J. Sivaswamy, K. Karan, and S. Krishnadas, “Optic disc and cup boundary detection using regional information,” IEEE International Symposium on Biomedical Imaging: From Nano to Macro, 2010.

[11] S. Lavanya, “Detection of anatomical structures in optical fundus images,” International Journal of Application or Innovation in Engineering & Managemen, vol. 2, no. 5, pp. 430--435, 2013.

[12] S. Sekhar, W. Al-Nuaimy, and A. K. Nandi, "Automated localisation of retinal optic disk using hough transform," in Proc.5th IEEE International Symposium on Biomedical Imaging: From Nano to Macro, 2008.

[13] A. Osareh, M. Mirmehdi, B. Thomas, and R. Markham, "Colour morphology and snakes for optic disc localisation," in Proc. 6th Medical Image Understanding and Analysis Conference, 2002.