

# DETECTION OF DIABETIC RETINOPATHY USING MACHINE LEARNING

Kirti Satpute<sup>1</sup>, Arsh Pakhare<sup>2</sup>, Gaurav Gaikwad<sup>3</sup>, Kunal Warudkar<sup>4</sup>, Vishal Bhat<sup>5</sup>

<sup>1</sup>Prof, Department of Computer Engineering, Sinhgad College of Engineering, Pune, Maharashtra, India

<sup>2</sup>Student, Department of Computer Engineering, Sinhgad College of Engineering, Pune, Maharashtra, India

<sup>3</sup>Student, Department of Computer Engineering, Sinhgad College of Engineering, Pune, Maharashtra, India

<sup>4</sup>Student, Department of Computer Engineering, Sinhgad College of Engineering, Pune, Maharashtra, India

<sup>5</sup>Student, Department of Computer Engineering, Sinhgad College of Engineering, Pune, Maharashtra, India

\*\*\*

**Abstract** - The purpose of this paper is to execute the survey of different literatures where a comprehensive study on Diabetic Retinopathy (DR) is done and different Machine learning techniques are used to detect DR. Diabetic Retinopathy (DR) is an eye syndrome in humans with diabetes which probably can damage the retina of the eye and may cause absolute visual impairment. Therefore, it is critical to detect diabetic retinopathy in the initial stage to avoid blindness in humans. Our goal is to detect the existence of diabetic retinopathy by applying machine learning classifying algorithms. Hence, we try and synopsise the various models and techniques used along with methodologies used by them and analyze the accuracies and results.

**Key Words:** Machine learning, Neural network, Diabetic Retinopathy, filters, feature extraction, pool layer

## 1. INTRODUCTION

Diabetes is a condition that impairs the body's ability to process blood glucose, either because the body does not generate enough insulin, or because the cells are unable to effectively use the insulin that's produced. The high blood glucose in diabetes is related to damage of the small blood vessels of the retina, which results in diabetic retinopathy (DR). Diabetic retinopathy can cause the blood vessels within the retina to leak fluid or haemorrhage (bleed), which can lead to a hazy or compromised vision. In its advanced stages, new irregular blood vessels proliferate on the surface of the retina, which may cause scarring and cell loss within the retina. One of the common complications of the Diabetes is Diabetic Retinopathy. It's a severe and widely spread disease. The threat of the disease increases with age and thus, middle aged and older aged diabetic people are vulnerable to Diabetic

Retinopathy. Laser surgery can be performed to prevent visual impairment or blindness. But presently there is no treatment that can bring back the vision that has already been lost. Detecting this disease is a time-taking and manual process that requires the skilled clinicians to examine and evaluate fundus photographs of the retina. Hence it is very crucial to detect Diabetic Retinopathy as early as possible.

## 2. LITERATURE REVIEW

### 2.1 Diabetic Retinopathy (DR) on Retinal Image [1]

In this paper, the principles of DR were studied which included stages, causes, symptoms, and risks involved with it along with basic concepts of the human eye and body related to DR. This study aims to give the direction for a researcher in order to suggest a new DR detection method. According to this study, the principal reason of DR is the unusual rise of glucose level. The early symptoms of DR are tiny capillary distention called as microaneurysms. DR advancement causes macular edema and exudates and also the cotton wool spot as well as neovascularization where at the later phase causes retinal segregation. The four stages of DR were classified as:

1. Mild Non-proliferative Retinopathy: The earliest stage where microaneurysms occur.

2. Moderate Non-proliferative Retinopathy: As the disease progresses, few blood vessels that deliver to retina are blocked.

3. Severe Non-proliferative Retinopathy: In this stage more blood vessels get blocked, which results in reduced blood flow to the areas of the retina. These

areas send signals to the body for growth of new blood vessels.

4. Proliferative Retinopathy: This is the progressive stage. This condition is called proliferative retinopathy. These new blood vessels are abnormal and delicate. These vessels do not cause symptoms or vision loss. Since they have thin and weak walls, they can leak blood, causing severe vision loss and even blindness.

The retinal image is a very important diagnostic tools and helps ophthalmologists which assisted by analysis by computers to perform diagnosis, treatment, and screening of various epidemic eye diseases including DR.

They state that there are no symptoms of DR at early stages nor any warning signals. For the first stage which is the Non proliferative diabetic retinopathy (NPDR), detection can be done only by fundus photography. For diminished vision fluorescein angiography is used to examine the rear part of the eye. In the second stage, neovascularization are formed at the rear part of the eye, they can burst, bleed and blur vision, because the new blood vessels are fragile. It is not severe when it occurs for the first me, it will leave a few spots in the vision. On fundoscopic exam, a doctor will see coon wool spots, flame haemorrhages, and dot-blot haemorrhages.

## 2.2 Automated Detection of Diabetic Retinopathy using Fluorescein Angiography Photographs [2]

To diagnose the existence and seriousness of Diabetic Retinopathy from Fluorescein Angiography photographs, Convolutional neural networks (CNNs) and denoising techniques were used. Data was provided by EyePacs consisting of fundus photographs with varying ranges of DR severity labelled by clinicians. The various CNN architecture models used were: 1. AlexNet: The first pretrained model used [8]. The model is operated by loading the pretrained weights, and only retrain the final fully connected layer to 4 predict 5 classes rather than 1000. Loading the pretrained model and retraining the final layer greatly improved on the results produced by the baseline, and generated our first legitimate results. A training

accuracy of 72.9 percent was attained, so they were evidently able to overfit their data. Fascinatingly, even as they continued to overfit more and more (loss 0.1), the confirmation accuracy remained comparatively constant. The accuracy results for AlexNet on varying numbers of classes is summarized below under the best learning rate and hyperparameters that were searched. 2. GoogLeNet: The second pretrained model used [9]. We loaded the pretrained weights into our network, and retrained the final layer to predict 5 classes rather than 1000. GoogLeNet seemed to perform marginally (12%) better than AlexNet in virtually all situations where both were tried. Similar to AlexNet, it was able to accomplish a notably greater training accuracy than validation accuracy (74.2% vs. 41.7%), signifying that it was overfitting the training data. Below sum up the accuracy results across varying class numbers: 3. Baseline: As a baseline, they built a convolutional neural network from scratch that acts as our control. The model is trained using randomized hyperparameter search. The baseline performed rather poorly. In the 2-class, 3- class, and 5-class cases, it functioned somewhat better than randomly guessing on the validation and test sets. When tested on the training set, though, it was able to execute unusually better than randomly guessing; it can be established that the network was at least able to learn some decision boundaries After analysing the images which were incorrectly classified, they realized few things which we co-occurring with the misclassified images. Firstly, images where existence of black space was more frequent tended to be misclassified. To rectify this, they tried to crop images where only the radial eyeball is present but not all images had black space, which caused them few problems. The color of the eyes varied a lot is the next main point. As the colours aren't distributed evenly between the classes, the models might learn that certain colours correspond to certain classes. Dark and corrupt images also cause an issue for the prediction by the models. A near random prediction is made.

### 2.3 Machine learning approach to automatic exudate detection in retinal images from diabetic patients [3]

**Table -1:**

classes	Accuracy
2	0.6695
3	0.5705
5	0.4073

**Table -2:**

classes	Accuracy
2	0.7105
3	0.5821
5	0.4168

**Table -3:**

	Accuracy	Recall	Precision
2 class	0.541	0.502	0.489
3 class	0.353	0.387	0.301
5 class	0.227	0.201	0.235

In this paper, they present a series of experiments on feature selection and exudates classification using naive Bayes and support vector machine (SVM) classifier. They first fit the naive Bayes model to a training set consisting of 15 features extracted from positive and negative images. Then perform SVM on the best training set of naive Bayes and repeatedly add the previously-removed features to the classifier. For

each combination of features, they perform a grid search to determine the best combination of hyperparameters (tolerance for training errors) and (radial basis function width). They compare the best naive Bayes and SVM classifiers to a baseline nearest neighbour (NN) classifier using the best feature sets from both classifiers. We discovered that the naive Bayes and SVM classifiers accomplish better results than the NN classifier. Before this, there have been several attempts to solve this problem. Few are based on thresholding and region growing, specialized features and morphological reconstruction techniques. These techniques are highly sensitive to image contrast. But above work mostly done on pupil dilated images. Since pupil dilation takes time and is uncomfortable for patients. So, in this paper they achieve practically useful exudate detection results on non-dilated fundus images. Feature extraction gave the following features: The pixel's intensity value after pre-processing, the standard deviation of the pre-processed intensity values in a window around the pixel, the pixel's hue, the number of edge pixels in a region around the pixel, the average intensity of the pixel's cluster, the size of the pixel's cluster, measured in pixels, the average intensity of the pixels in the neighbourhood of the pixel's cluster, the ratio between the size of the pixel's cluster and the size of the optic disc, the distance between the pixel's cluster and the optic disc, six difference of Gaussian (DoG) filter responses as DoG1, DoG2, DoG3, DoG4, DoG5 and DoG6. Using Naïve Bayes theorem on all 15 features. The resulting classifier had an overall PR 64.67%. And then numerous features are removed in order to get more PR value and this is done until the PR stopped enhancing. For SVM algorithm the best performance was obtained using 10 features with maximum PR of 72.67%. NN classifier with Euclidean and Mahalanobis distance obtained a PR of 65.15 and 64.99%, respectively. Both the naive Bayes classifier and the SVM sometimes miss faint exudates and erroneously detect as exudate image artifacts or retinal structures that share some characteristics with exudates. It is time consuming as many feature selection tests need to be made.

#### 2.4 Detection and Classification of Diabetic Retinopathy using Retinal Images [4]

The basis of the categorization of several stages of diabetic retinopathy is the detection and quantification of blood vessels and hemorrhages existing in the retinal image. Retinal vascular is split up applying the contrast between the blood vessels and surrounding background. Hemorrhage candidates were noticed using density analysis and bounding box techniques. Categorization of the different stages of eye disease was done using Random Forests technique based on the area and perimeter of the blood vessels and haemorrhages. The objectives of this work are: detection of blood vessels, detection of haemorrhages, classification of the detections into normal, moderate non-proliferative diabetic retinopathy (NPDR) and severe NPDR. An advanced non-parametric Tree-type classifier – Random Forests (RF) is used for Categorisation. Six features are area and perimeter in each of the R, G, B components of the blood vessels and haemorrhages were extracted. Area is the number of white pixels (blood vessel and haemorrhage candidates) existing in the vessels and perimeter was determined by the number of pixels present on the boundary of the vessels. These extracted features were used as inputs to the RF classifier for classifying the three stages of retinal images. Normal cases were classified with 90% accuracy while moderate and severe NPDR cases were 87.5% accurate.

#### 2.5 Detection of Diabetic Retinopathy Using K-Means Clustering and Self-Organizing Map [5]

Feature extraction of retinal images and categorisation is the standard process to analyse and diagnose diabetic retinopathy. In this paper, they used K-means algorithm which is used to obtain features and the classifier used is Self-Organizing Map (SOM) classifier. They firstly converted the images into grayscale image and after that applied K-means clustering. The grayscale image output after clustering has six different intensities of grey. Each of the intensity signifies one cluster. The optic disc and background are well grouped and clearly defined because of K means clustering. The centroid values

fetches in K-means clustering are then fed into the Self-organizing map artificial neural network classifier and the values are simplified into points on the weight map. The neurons will then position themselves to wrap around these points so as to best describe them. This is how the self-organizing map trains its neurons. The classifier divides the cluster centroids of the normal class and the diabetic retinopathy class. In this work, the red, blue, green layers (RGB) of the coloured fundus image are input into a K-means clustering algorithm that outputs individual cluster centroid values for each RGB layer per image. In this paper, the SOM is able to show a 3D weighted map illustrating the noticeable difference between the normal and diabetic retinopathy images. But this model only classifies whether the DR is present or not, it does not classify the DR into different stages.

#### 2.6 Automated detection of diabetic retinopathy using SVM [6]

This paper proposes a computer aided diagnosis centered on the digital processing of retinal images in order to help people detecting diabetic retinopathy in advance. The principal objective is to automatically classify the grade of non-proliferative diabetic retinopathy (DRNP) at any retinal image. The Messidor database [10] consists of 1200 eye fundus color numerical images of the posterior pole acquired by 3 ophthalmologic departments using a color video 3CCD camera on a Topcon TRC NW6 non-mydratric retinograph with a 45 degrees field of view. The retinal images were captured using 8 bits per color plane at 1440×960, 2240×1488 or 2304×1536 pixels. 800 images were attained with pupil dilation (one drop of Tropicamide at 0.5%) and 400 without dilation. The features extracted were: blood vessels, Microaneurysms and hard exudates. The 8 quantitative features used by the classifier are: Standard deviation of the red component, Standard deviation of the green component, Standard deviation of the blue component, Blood vessel density, Possible number of microaneurysms, Actual number of microaneurysms, Density of hard exudates, Green component entropy. There are 2 main results in this is DRNP detection and DRNP grade classification. For detection, they used 301

retinal images, 152 with grade 0 and 149 with grade 3. They trained a SVM classifier with all the features of these images and then examined it through a 10-fold cross-validation process. The performance was also enhanced selecting the most applicable features and SVM parameters. For grade classification they used 400 retinal images. A multi-class SVM (one-to-one) classifier was trained with all the features and then tested using a 10-fold cross-validation. Their proposal has been tested on a database of 400 retinal images marked according to a 4-grade scale of non-proliferative diabetic retinopathy. As outcome, a maximum sensitivity of 94.6% and a predictive capacity value of 93.8% was achieved.

### **2.7 Detection of Diabetic Retinopathy using Image Processing and Machine Learning [7]**

In this paper, detection of diabetic retinopathy in fundus image is performed by image processing and machine learning techniques. Probabilistic Neural Network (PNN) and Support vector machines (SVM) are the two models implemented for detection of diabetic retinopathy in fundus image and their results analyzed and compared. A low power microscope named ophthalmoscope or the fundus camera is attached with a digital camera and captures the image of interior surface of the eye which includes retina, optic discs, macula and the blood vessels. The images are usually obtained from the posterior pole's view including the optic disc and macula. Images had the resolution of 1280 x 1024 or 700 x 605 Pixels. Image acquired from fundus camera is in 24-bit JPEG format. The grey scale conversion system converts the RGB image obtained from the Fundus camera into grey image. Adaptive Histogram Equalization computes several histograms and redistributes the lightness values across the image and enhances the contrast values of the image followed by the adaptive histogram equalization, noise in the image is removed by applying the matched filter response (MFR). The last step of the processing includes the clustering by Fuzzy c-means which makes the blood vessels of the image distinctly visible and helps in rating the severity of the disease and automated detection of diabetic retinopathy. After processing the image, features such as Radius,

Diameter, Area, Arc length, Centre Angle and Half area are estimated for each image. Features extracted are passed on to the machines learning algorithms such as Support Vector machine and Probabilistic Neural Network for classifying the image into Normal, Non proliferative diabetic retinopathy (NPDR) and Proliferative diabetic retinopathy (PDR). Retinal images are circular in shape, therefore circular features are extracted. After the pre-processing steps, circular features of retinal images like Radius, Diameter, Area, Arc length, Centre Angle and Half Area are calculated. Result for PNN: Sensitivity 81.42% Specificity 100%.

Result of SVM: Sensitivity 81.42% Specificity 100%.

## **3. PROPOSED SYSTEM**

### **3.1 Problem Statement**

“To detect diabetic retinopathy using machine learning.”

### **3.2 Problem Elaboration**

Diabetic retinopathy (DR) is a disease which causes blindness in people having diabetes. Currently, to detect DR, medical staff has to thoroughly examine images of the retina manually taken by the technique of Fundus photography. This is time consuming. We proposed a model to detect DR using machine learning techniques such as Neural networks to make the detection process automated as well as accurate.

### **3.3 Proposed Methodology**

Machine learning consist of a number of stages to detect retinopathy in the fundus images that includes converting image to suitable input format, denoising and various preprocessing techniques. It also includes training a model with a training set and validating with a different testing set. Method proposed in this project can be listed in two steps: Image Preprocessing, and Supervised learning and Feature Extraction. First, the images are preprocessed. They are converted from RGB to grayscale. Proper resizing of image is also done. As the images are heterogeneous they compressed into a suitable size and format. Layer separation will also performed. For making intensity variations uniform

histogram equalization to the image can be applied. Morphological operation will be done to remove the noise present in the background of retinal image. We then plan to use Convolutional neural network (CNN) architecture for feature extraction and prediction of the class of DR. A CNN is able to capture the temporal and spatial dependencies in images and its better due to the decrease in parameters used and weight reusability. It has the ability to train to understand the complexity of the image more efficiently.

### 3.4 Project Architecture:

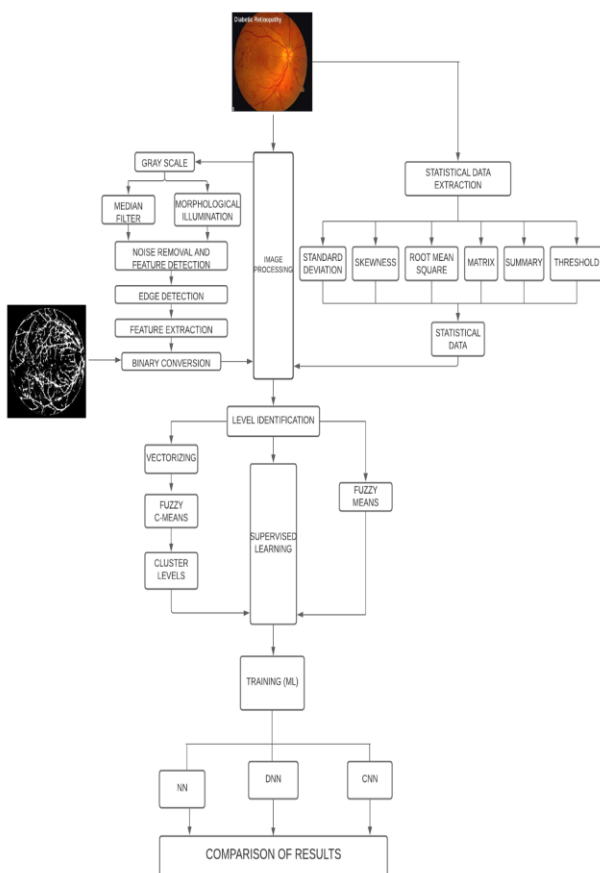


Fig -1: Project Architecture

### 4. CONCLUSIONS

This paper summarizes our study and review of few literatures related to the detection of Diabetic retinopathy. A number of studies use neural networks and image processing for detection using different architectures. It is certain that using machine learning

techniques will give us good results along with good accuracy for prediction. In this paper, we explored the potential usage of the CNN in retinal image classification. Due to the tedious manual methods by medical personnel, an automated system can reduce the labor involved in diagnosing large quantities of retinal images significantly.

### 5. REFERENCES

[1] Wan Mustafa, Aimi Abdul-Nasir, Haniza yazid, "Diabetic Retinopathy (DR) on Retinal Image", IOP publishing 1st International Conference on Green and Sustainable Computing (ICoGeS) 2017 25-27 November 2017, Kuching, Sarawak, Malaysia

[2] Marco Alban, Tanner Gilligan, "Automated Detection of Diabetic Retinopathy using Fluorescein Angiography Photographs" Proceedings of the International Conference on Smart Electronics and Communication (ICOSEC 2020) IEEE Xplore Part Number: CFP20V90-ART; ISBN: 978-1-7281-5461-9

[3] Akara Sopharak a\* , Matthew N. Dailey b ,Bunyarit Uyyanonvara a Sarah Barman c ,Tom Williamson d , Khine Thet Nwe b and Yin Aye Moe b, "Machine learning approach to automatic exudate detection in retinal images from diabetic patients", January 2010 Journal of Modern Optics 57

[4] Kanika Verma, Prakash Deep and A. G. Ramakrishnan, Senior Member, IEEE, "Research Paper 4: Detection and Classification of Diabetic Retinopathy using Retinal Images", Published in: 2011 Annual IEEE India Conference

[5] Wong Li Yun and Muthu Rama Krishnan Mookiah Department of Electronics and Computer Engineering, Ngee Ann Polytechnic, Singapore 599489, "Detection of Diabetic Retinopathy Using K-Means Clustering and Self-Organizing Map Journal of Medical Imaging and Health Informatics, December 2013

[6] Enrique V. Carrera, Ricardo Carrera, Andres Gonzalez, "Automated detection of diabetic retinopathy using SVM ", August 2017

[7] Salman Sayed, Dr. Vandana Inamdar , Sangram Kapre , "Detection of Diabetic Retinopathy using Image

Processing and Machine Learning” , Vol. 6, Issue 1, January 2017

[8] Suvajit Dutta, Bonthala CS Manideep, Syed Muzamil Basha, Ronnie D. Caytiles<sup>1</sup> and N. Ch. S. N. Iyengar, “Classification of Diabetic Retinopathy Images by Using Deep Learning Models” , Vol. 11, No. 1 (2018)

[9] Alex Krizhevsky, Ilya Sutskever, and Geoffrey E. Hinton. Imagenet classification with deep convolutional neural networks. In F. Pereira, C. J. C. Burges, L. Bottou, and K. Q. Weinberger, editors, Advances in Neural Information Processing Systems 25, pages 1097– 1105. Curran Associates, Inc., 2012.

[10] Christian Szegedy, Wei Liu, Yangqing Jia, Pierre Sermanet, Scott Reed, Dragomir Anguelov, Dumitru Erhan, Vincent Vanhoucke, and Andrew Rabinovich. Going deeper with convolutions, 2014.

[11] E. Decencière, X. Zhang, G. Cazuguel, B. Lay, B. Cochener, C. Trone, P. Gain, R. Ordonez, P. Massin, A. Erginay, B. Charton, and J.-C. Klein, “Feedback on a publicly distributed database: the Messidor database,” Image Analysis Stereology, vol. 33, no. 3, pp. 231–234, Aug. 2014.